



ELSEVIER

Contents lists available at ScienceDirect

Human Movement Science

journal homepage: www.elsevier.com/locate/humov



Real-time MRI comparisons of brass players: A methodological pilot study



Peter W. Iltis^{a,b,*}, Erwin Schoonderwaldt^b, Shuo Zhang^c, Jens Frahm^c,
Eckart Altenmüller^b

^aDepartment of Kinesiology, Gordon College, Wenham, MA, USA

^bInstitut für Musikphysiologie und Musikermedizin, Hochschule für Musik, Theater und Medien, Hannover, Germany

^cBiomedizinische NMR Forschungs GmbH am Max-Planck-Institut für biophysikalische Chemie, Göttingen, Germany

ARTICLE INFO

PsychINFO classification:
2260

Keywords:
Magnetic resonance imaging
Brass players

ABSTRACT

This paper describes the use of real-time MRI at 30 frames/s in studying motor function within the oropharyngeal cavity of a trumpet, horn, trombone, and tuba player. Using Image J and customized MB-Ruler Pro software, analyses of discrete 33.3 ms snapshots of motion extracted from real-time MRI films obtained during an ascending five note sequence performed on a plastic practice device (B.E.R.P.) revealed inter-instrument differences in oropharyngeal cavity size and tongue conformation when moving from lower to higher notes. Tuba and trombone show a progressive decrease in oropharyngeal area featuring an upward and forward displacement of the tongue. Trumpet showed progressive increases in oropharyngeal area, with the posterior compartment showing the largest change, while horn essentially showed no change. A novel dynamic quantitative analysis method is also described utilizing Matlab. This method employs user-specified line profiles, aligned to the direction of the movement of interest. It takes advantage of time-varying pixel luminescence to derive spatial and temporal gradients. These gradients make possible the acquisition of kinematic data to describe movement in terms of slower position changes (spatial gradient) as well as fast, articulatory movements (temporal gradient). Spatial gradient analysis for the trumpet player demonstrates a progressive raising of the tongue during the ascending five note exercise. Temporal gradient analysis of double-tonguing revealed similarities in range of motion, anti-phase behavior, and frequency across instruments with

* Corresponding author at: Department of Kinesiology, Gordon College, Wenham, MA, USA. Tel.: +1 978 867 4088.
E-mail address: peter.iltis@gordon.edu (P.W. Iltis).

respect to movements of the tongue tip and back of tongue. The paper concludes by making recommendations for extending these methods to studying musician's dystonia.

© 2015 Elsevier B.V. All rights reserved.

1. Introduction

Information pertaining to motor functions of the structures within the oral and pharyngeal cavities of brass players is poorly understood. While both pedagogical books and scientific papers have been written about the normal and disordered function of the facial muscles in forming the brass player's embouchure (the vibrating interface formed between the upper and lower lips that initiates musical tone) (Epstein, 2013; Farkas, 1962; Fox, 1974; Frucht, 2009; Frucht & Estrin, 2010; Gardner, 2002; Rider, 2006; Steinmetz et al., 2013), much less attention has focused on the tongue and its role in the formation of the oropharyngeal cavity during tone production. Most publications commenting on the role of the tongue comprise pedagogical books explaining the writer's subjective perception of what happens inside the mouth. They generally describe relationships between assumed tongue positions and the apparent ease of tone quality and tone production while playing through the frequency range of the instrument (Epstein, 2013; Farkas, 1962; Fox, 1974; Gardner, 2002; Reynolds, 1997; Rider, 2006).

Conventional MRI allowing the acquisition of static images within the mouth and throat affords a way to image isolated events during brass playing. Specifically, MRI provides accurate depictions of conformations within the mouth and pharynx during note iterations that can bring greater objectivity and consistency to diverse teaching methods. Despite this potential, only a few MRI studies have been conducted to visualize internal configurations of the oropharyngeal cavity during wind instrument playing. Two of these examined changes in oropharyngeal cavity position in didgeridoo performers, one during circular breathing (Wiggins & Storey, 2010) and a second during performance of notes that used different vocal tract configurations to vary tonal characteristics (Fletcher, Hollenberg, Smith, & Wolfe, 2001). A third paper by Kaburagi, Yamada, Fukui, and Minamiya (2013) involved studying static MRI images obtained over 30–40 s in order to compare vocal tract volumetric area characteristics when playing low, mid, and high pitched notes in a professional trumpet player. The authors reported a tendency for a reduction in anterior cross-sectional area measurements, and an increase in posterior cross-sectional area measurements as the performer moved from low to high notes. While interesting, these experiments were inconsistent in the approaches they employed to describe and quantify observed phenomena. In addition, the methods employed fall short of depicting dynamic phenomena occurring in the mouth during performance.

As an alternative, sonography has been employed to visualize activity within the mouth during wind instrument performance (Angerstein, Isselstein, Lindner, Aurich, & Massing, 2009; Zielke, Muth, Massing, & Angerstein, 2012). In these studies, tongue movements were compared between brass, reed and flute players, showing that in executing a sequence of notes, brass players demonstrate the largest tongue motion amplitudes in moving between notes. Though relatively inexpensive and comfortable for subjects, sonography falls short of attaining the anatomical resolution that is possible with MRI.

With the recent development of high-speed (33.3 ms acquisition time yielding 30 Hz frame rate) real-time MRI technology (Uecker, Zhang, Voit, Merboldt, & Frahm, 2012; Uecker et al., 2010), the potential for studying both discrete events and the oropharyngeal dynamics of brass players is now possible. This technology has received notable attention in examining speaking (Echternach et al., 2008; Engwall, 2003; Hagedorn, Proctor, Goldstein, Tempini, & Narayanan, 2012; Niebergall et al., 2013), swallowing (Barkhausen et al., 2002; Olthoff, Zhang, Schweizer, & Frahm, 2014; Zhang, Olthoff, & Frahm, 2012), and cardiovascular function (Horvath, Li, Mazilu, Guttman, & McVeigh,

2007; Joseph et al., 2012, 2013; Miller et al., 2012; Voit et al., 2013; Zhang, Uecker, Voit, Merboldt, & Frahm, 2010). In contrast, only one publication to date has used a similar technology (4–10 Hz frame rate) to study oropharyngeal motor functions in brass musicians (Schumacher et al., 2013). In this paper, Schumacher et al. used fast 3-T MRI system to describe mouthpiece placement and angle, velopharyngeal movements, and changes in oropharyngeal areas in trumpet players executing a set of performance exercises. These exercises involved performing scale sequences, octave intervals, tonguing and multiple tonguing exercises, and a simple melody under three performance conditions: (1) simply buzzing the lips, (2) buzzing on a mouthpiece, and (3) playing on a mouthpiece/tube system with a cardboard bell attached. The principal findings were that increasing tone pitch as well as increasing loudness (dynamics) occurs with concomitant increases in the free space of the oropharyngeal cavity, though some inter-individual variability was shown among the 12 subjects.

This study raises several interesting questions. First, the finding of increasing oropharyngeal volumes with higher frequency notes stands in contrast to the experience-based, subjective contention of several brass pedagogues (Epstein, 2013; Farkas, 1962; Fox, 1974; Gardner, 2002). It is noteworthy that these brass teachers do not constrain their comments to trumpet playing, and lacking MRI studies on other brass instruments, an objective assessment of their opinions in relation to the Schumacher et al. findings is not possible. It is also interesting that no results are reported comparing the three performance conditions noted previously. The sensory feedback provided by each of these conditions seemingly must vary considerably between buzzing on the lips or mouthpiece and playing on a tube system where note production is constrained to a harmonic series dictated by the length of the tube (Farkas, 1962; Fox, 1974; Rider, 2006). Additionally, though these investigators reported a reasonably fast frame rate of 4–10 Hz, none of the analyses that were reported took full advantage of this, and faster rates are now possible. Apparently, only static, sagittal images of isolated events were used for most of the analyses, leaving questions regarding the dynamics of motor function unanswered. Finally, since no dynamic analyses were performed, a useful systematic method for studying temporal phenomena in brass players is yet to be determined.

The purpose of the current pilot investigation is to address some of these issues by (a) describing a method for further developing a set of quantifiable dependent variables that are useful for measuring conformational changes within the oropharyngeal cavity during discrete performance events, (b) applying this method in comparing brass performers of different instruments (trumpet, horn, trombone, and tuba) and (c) describing an analysis method that takes advantage of fast (30 Hz), real-time MRI providing qualitative and quantitative dynamic information during tone production. Finally, suggestions are made regarding the development of MRI-compatible brass instruments that better simulate actual performance, allowing the application of this methodology to a wider population, including brass players with embouchure dystonia.

2. Materials and methods

2.1. Subjects, performance device and testing protocol

For this pilot study, one performer for each of four instruments, trumpet, horn, trombone and tuba, comprised our sample. Three of the performers were students at the Hannover University for Music, Drama and Media (trumpet-25 years old, trombone-22 years old, tuba-22 years old), and the horn player was a 32 year old amateur and a music school graduate.

Two performance tasks were executed using a plastic mouthpiece, and a commercially-available practice device known as a B.E.R.P. (Musical Enterprises, Fairfax, California). The acronym stands for “buzz extension resistance piece”, and when attached to a mouthpiece, it allowed the performers to play notes while simulating the aerodynamic resistance afforded by an actual brass instrument. Its compact size and non-ferromagnetic properties made it easy to employ while in the MRI magnet. Because the instruments have their fundamental pitch in different parts of the audible frequency range, all performance tasks involved playing notes that were in the same relative range for each instrument.

The first task consisted of playing an ascending sequence of five notes spanning 2 octaves. Each note was initiated by the tongue, and sustained for approximately 1 s. The second task involved playing repetitions of a single note using a double-tonguing technique. Fig. 1 depicts these exercises for the horn player. Three trials for each task were performed, and the trial comprising the most stable performance was chosen for analysis.

2.2. Magnetic resonance imaging

All studies were conducted at 3 T using a commercial MRI system (TIM Trio, Siemens Healthcare, Erlangen, Germany) and a body coil for radiofrequency (RF) excitation. Subjects were examined in a supine position and MRI signals were acquired by combining a small flexible 4-channel receiver coil covering the lower face (Siemens Healthcare, Erlangen, Germany) with a bilateral 2×4 array coil centered to the thyroid prominence on both sides of the neck (NORAS MRI products, Hoechst, Germany).

Successive image acquisitions during trials relied on a highly under sampled RF-spoiled radial FLASH MRI sequence with image reconstruction by regularized nonlinear inversion as described (Uecker et al., 2010). The imaging parameters included a repetition time of 2.22 ms, an echo time of 1.44 ms, a flip angle of 5° , a $92 \times 192 \text{ mm}^2$ field of view (FOV), an in-plane resolution of $1.5 \times 1.5 \text{ mm}^2$, and section thickness of 10 mm. Individual images were obtained from a single set of 15 spokes, which resulted in a temporal resolution of 33.3 ms or 30 fps.

Prior to dynamic magnetic resonance imaging, scout images (FOV $192 \times 192 \text{ mm}^2$) were obtained in the mid-sagittal plane using the same FLASH sequence but with full radial sampling and conventional fast Fourier transform (FFT) reconstruction. Note production was then studied by multiple real-time MRI movies in a mid-sagittal orientation. The mid-sagittal plane covered the entire vocal tract from the lips, tongue, and nasopharynx to the larynx, as well as the upper airway, including vocal folds.

During data acquisition, online image control was ensured by sliding-window FFT reconstructions of 75 spokes obtained by combining five consecutive data sets, each comprising 15 spokes at complementary positions (Zhang, Block, & Frahm, 2010). At the same time, the incoming data were automatically exported for immediate offline reconstruction by regularized nonlinear inversion to a computer equipped with 8 GTX580 graphical processing units, each providing 512 processing cores (Nvidia, CA). Once the offline calculation was completed, the images were reimported to the MRI system's database.

2.3. Discrete static analysis: Ascending sequence trials

For all subjects, each of the five notes in the ascending five note exercise was analyzed by visually and audibly determining the midpoint from the moment of note initiation to the moment of note cessation from the MRI films. Because these MRI films were a stack of individual images, each separated by 33.3 ms, it was possible to identify the precise image number and time corresponding to this midpoint. The MRI films were then imported into the FIJI version of Image J software (Rasband, 1997–2012) for further analysis. Image J allows a vast array of analytical procedures to be performed on an entire stack of images.



Fig. 1. Performance exercises (horn exercise is illustrated).

For each image series, a “standard position” frame was identified in which the jaw was closed with the tongue resting against the back of the upper teeth, as well as along the hard palate. Because the solid material of the teeth provide no MRI signal, the boundaries of the upper and lower teeth were visualized as the dark area between the visible inner surface of the lips and the visible anterior border of the tongue. From this frame, four anatomical landmarks were manually digitized to create image overlays that could be superimposed and re-adjusted on any subsequently-selected frame. These included the upper and lower teeth, the hard palate, and the posterior border of the oropharynx, landmarks that supported the accuracy of further analyses. These landmarks are incorporated into Fig. 2 which is further described below. With the overlays appropriately positioned, each discrete event image was saved for subsequent quantitative analyses.

To enable quantification of static image data, each discrete event image depicting a sagittal view of the head was imported into a customized software program, MB-Ruler Pro: MRI-Grid (Bader, 2014) and automatically calibrated (0.75 mm/pixel). This program allowed quantitative image analyses by superimposing a standardized grid (MRI-Grid) over the image, and requiring the user to digitize a precise series of landmarks within this grid. The following description of the digitizing process results in the image depicted in Fig. 2. First, the baseline for the grid was defined by digitizing a point at the inferior border of the upper front teeth and another at the anterior border of the third intervertebral disc. A line was then automatically created between these points, and, using the center point of this line as the origin, a series of seven rays was automatically projected outwards at 0°, 30°, 60°, 90°, 120°, 150°, and 180°. Two landmarks from the origin were then hand-digitized and automatically measured along each of these rays; the first was the linear distance from the origin to the dorsal surface of the tongue, and the second was the linear distance from the tongue surface across the oral or pharyngeal cavity to the next intersection with tissue, whether that be the teeth, the hard or soft palate, the back of the pharynx or the back of the larynx. These measures provided a means of quantitatively defining the relative position of the tongue within the mouth.

Next, the area of space within the mouth was divided into an anterior and posterior compartment and measured. Using the 90° ray as the dividing line between the anterior and posterior oral cavities,

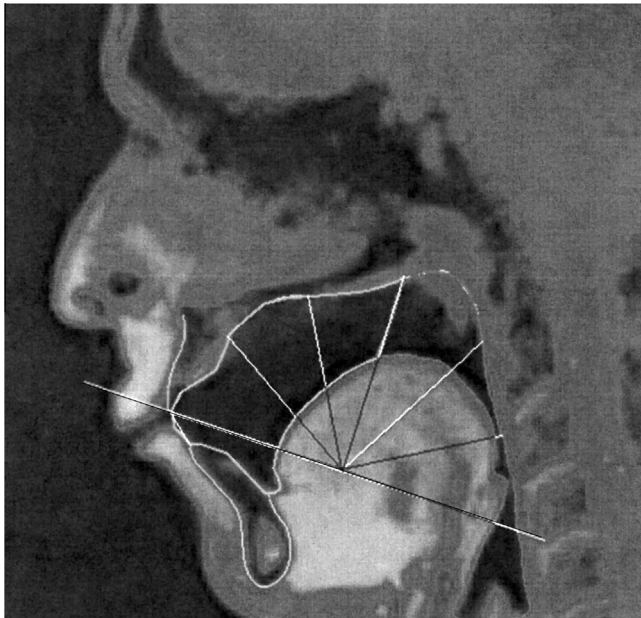


Fig. 2. Sagittal view showing grid system and the use of anatomical landmarks (teeth, hard palate, posterior border of oropharynx) to digitize the oral cavities.

the border areas within the mouth and throat were hand-digitized, and subsequently quantified by the software. The inferior border of the posterior oral cavity was defined by a line running anteriorly from the most distal and posterior border of the pharyngeal cavity to the anterior border. Because of the relatively small contribution of both the epiglottis and the velum to the actual volume of the posterior area and the difficulty of consistently determining the borders of these two structures, no attempt was made to exclude these from the measured area.

The reliability of the technique was established by performing three separate analyses on each of five discrete performance images, each performance/analysis combination presented in random order. The average coefficient of variation across all dependent variables was 2.4% (range .1–7.1%).

2.4. Dynamic analyses: General methodology

One of the main challenges was to develop a method for extracting temporal information from the sequence of images that was suitable for quantitative analysis. For this purpose a method was devised in Matlab (Matlab v2013b, including the Image Processing Toolbox, and the Signal Processing Toolbox), consisting of three steps. In the first step, the time-varying pixel luminescence across image frames was projected on a selection of straight lines drawn on top of the image, resulting in line profiles representing movements along these lines (see Fig. 3 and video TPT-2 Oct). This could be done by using the same radial 7 line grid as described above, or using any combination of lines representing the movement information of interest. Fig. 3 shows the use of two such lines to study movements of the tongue tip and larynx during execution of the ascending five note sequence. In the sagittal view (left panel), line 1 is positioned along the movement path of the tongue tip, and line 2 along the movement path of the larynx. The corresponding line profiles are depicted to the right of the sagittal view, with the tongue tip and larynx in the upper and lower panels, respectively. This choice of line profiles has been shown to be useful for revealing co-articulation phenomena in fast-MRI recordings of speech sequences (Niebergall et al., 2013). In video analysis this type of representation is also known as spatio-temporal slicing (Ngo, Pong, & Zhang, 2003; Pan, Li, Ba, Zhang, & Tang, 2006).

In the second step, the luminescence gradient was calculated, either along the spatial (vertical) dimension or the temporal (horizontal) dimension, representing the rate of change of pixel luminescence along the selected dimension. Optionally, filtering can be applied before the calculation of the gradient in order to reduce the influence of noise. Fig. 4 shows the gradients in both directions for

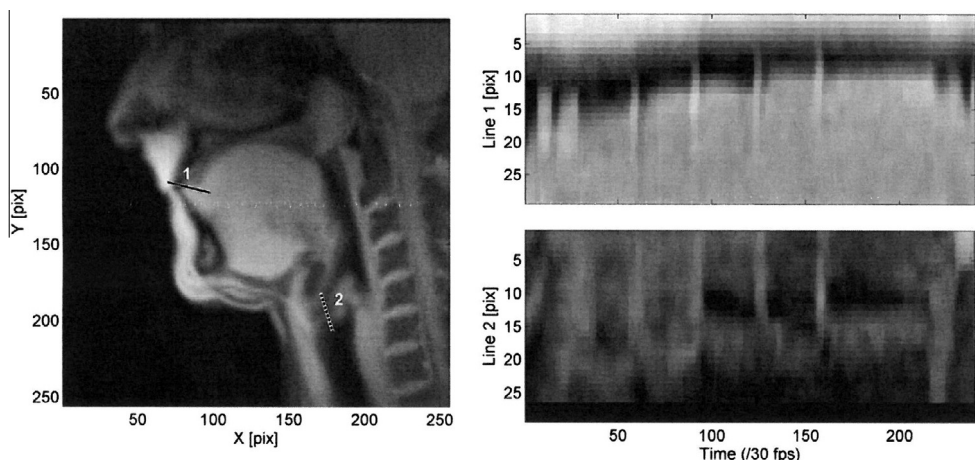


Fig. 3. Example of line profiles, created using the motion analysis toolbox in Matlab. The left-hand panel shows the sagittal view with projection lines positioned to illustrate the movements of the tongue tip (profile line 1) and the anterior tongue surface (profile line 2). The two right-hand panels show the respective line profiles of pixel luminescence changes during performance of the ascending five note exercise.

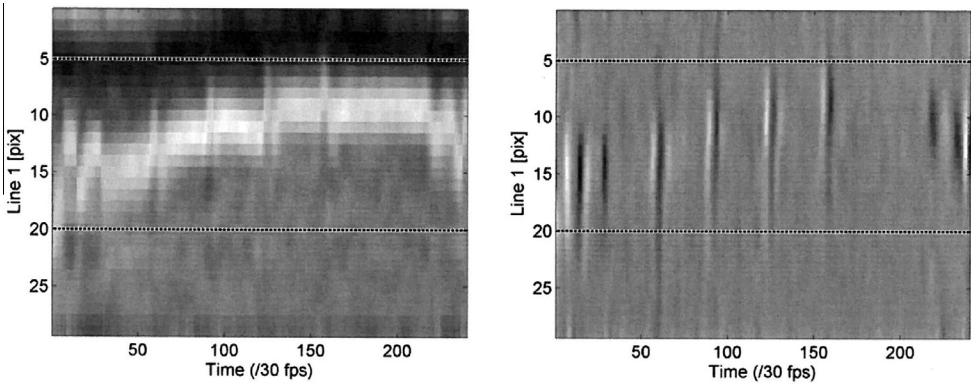


Fig. 4. Example of the spatial gradient (left panel) and the temporal gradient (right panel) of a line profile located at the tongue tip during performance of the ascending five note exercise (profile line 1 from Fig. 3).

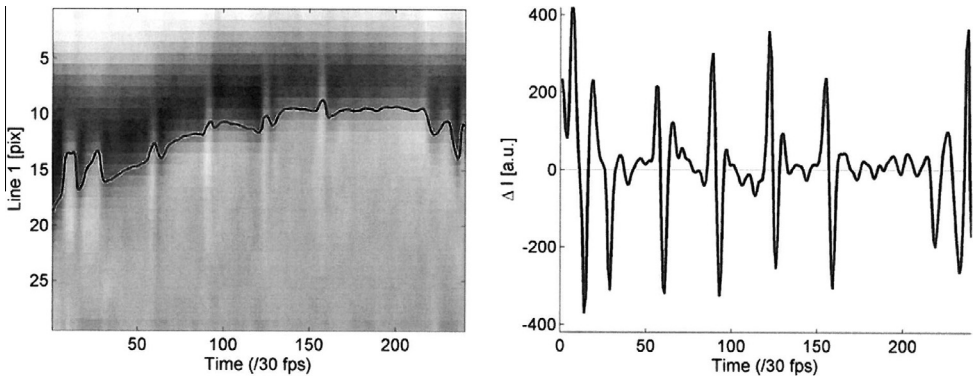


Fig. 5. Left panel depicts the centroid plotted on line profile 1 taken from Fig. 3 during the ascending five note exercise. The right panel shows time series data calculated from the temporal gradient representation of the same profile line.

the movement of the tongue tip based on profile line 1 shown in Fig. 3. The spatial gradient profile (Fig. 4, left panel) emphasizes the edge locations of moving structures. It is suitable for showing slow changes (e.g., the position of the tongue during execution of the ascending five note exercise). The temporal gradient profile (Fig. 4, right panel) emphasizes temporal fluctuations of pixel luminescence, and is therefore most suitable for the analysis of fast articulatory movements (e.g., rapidly changing note attacks).

In the third step, movement features were extracted in the form of time-series data. This was achieved in different ways, depending on how the relevant information needed to be represented. For example, from the spatial gradient profile of line 1 shown in the left panel of Fig. 4, the edge location of the tongue was estimated by a frame-wise centroid calculation along the spatial (vertical) dimension. Since the centroid (i.e., a weighted average of pixel luminescence values) is sensitive for the influence of outliers, it was important to make sure that the edge of interest was isolated by selecting the appropriate range of pixels, and if necessary by erasing (i.e., setting to zero) potentially disturbing parts of the profile. As an example, the location of the edge of the tongue during the ascending sequence trial by the trumpet player as estimated using this approach is projected on

top of the original line profile in the left panel of Fig. 5. In this case the selected pixel range across which the centroid was calculated was 5–20.

From the temporal gradient profile, a time series representation was obtained by simply selecting a horizontal line. In such a case, the time series data simply represent the change rate of pixel luminescence of a single pixel during the trial. However, as the pixel location of the peaks and troughs might vary throughout the duration of the trial, as in the example shown in Fig. 4 (right panel), an alternative approach involved taking the average across a selected range of pixels. An additional advantage of averaging is that noise is further reduced. For the chosen example the resulting time series data based on an average of pixel range 5–20 is shown in Fig. 5 (right panel). This representation clearly reflects the temporal characteristics of the quick tongue tip actions during the attacks.

2.5. Dynamic analyses: Double-tonguing

In the current pilot study, dynamic analyses were conducted on the double-tonguing exercise for comparison of frequency and range of motion of the tongue between the four instrumentalists. Double-tonguing requires a performer to execute tongue movements that produce the consonants, “T–K”, a rapid cycle that repeats for as long as the effect is needed. The dynamic analysis of this technique was performed as follows. First, two line profiles were extracted, one corresponding to movements at the tip of the tongue (“T”), and the other relating to movements of back of the tongue (“K”) (see Fig. 9 and video TBN-double tonguing). Second, the temporal gradients of both line profiles were calculated. Third, the range of motion of both parts of the tongue was determined visually from inspection of the line and the gradient profiles in combination with the average luminescence and luminescence standard deviation curves that were generated by the customized Matlab software. The latter curves, in particular the standard deviation curves, revealed the pixel luminescence variability along the lines, and where that variability was high, movement was assumed to be occurring. Fourth, time series data were extracted by taking the average of the temporal gradient across the spatial dimension, including only the identified range of motion. Finally, the time series data were used to calculate the correlation coefficient of the two movement components of the tongue (“T” and “K”), and the frequency of the movement was estimated from the peaks of the amplitude spectra obtained by a Fourier transform.

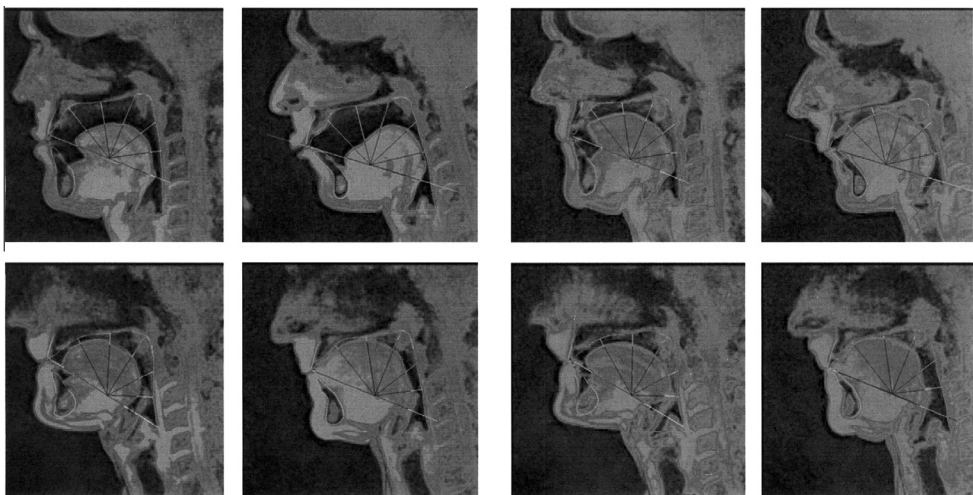

Fig. 6. Sagittal view of tuba, trombone, trumpet, and horn (images viewed clockwise from upper left in both groupings of four) playing the root (left set of four) and the second octave (right set of four).

3. Results

3.1. Discrete analyses of the ascending five note exercise

The left grouping of four images in Fig. 6 depicts selected sagittal views for all four instruments (tuba, trombone, trumpet and horn, clockwise from top left). These images were taken from the real-time MRI films while playing the lowest note in the sequence (root) and the right grouping illustrates the same views while playing the top note (octave 2). There were marked differences in the shape and size of anterior and posterior areas between instruments as they played both notes as well as in how they changed moving from the lowest to the highest notes.

Fig. 7 depicts changes in these areas throughout the five note sequence for each instrument. For the tuba and trombone, the trend was for a decrease in total area as a function of both anterior and posterior areas as the performer progressed from the lowest to the highest notes. The total degree of decrease in anterior area was the greatest (decrease of 44%/25% and 75%/30% for anterior/posterior areas in tuba and trombone, respectively). These patterns were not replicated in the horn and trumpet players, and in fact, the total oropharyngeal area of the trumpet player tended to increase across the 2 octaves, largely as a function of larger posterior area values.

With respect to the radial segment lengths along the 0°–180° rays, responses were different as well between low brass and higher brass instruments. This was best illustrated in comparing the trombone to the trumpet as seen in Fig. 8 depicting the percent composition (tongue vs. cavity) of the total oropharyngeal area along each ray. For the trumpet, the anterior area change (represented by bars 0°–30°) was characterized by a forward and upward projection of the tongue at both extremes of the register while for the trombone, a marked forward and upward shift of the tongue occurred when moving between the lowest (root) to the highest (8Va2) notes. Trends were respectively similar in comparing the tuba and horn.

3.2. Dynamic analyses of double-tonguing

In all instrumentalists the movement of the tongue in the double-tonguing exercises was characterized by a stable, continuous coordinative pattern involving the anterior-posterior movement of the tongue tip and the down- and upward movement of the back of the tongue (see video

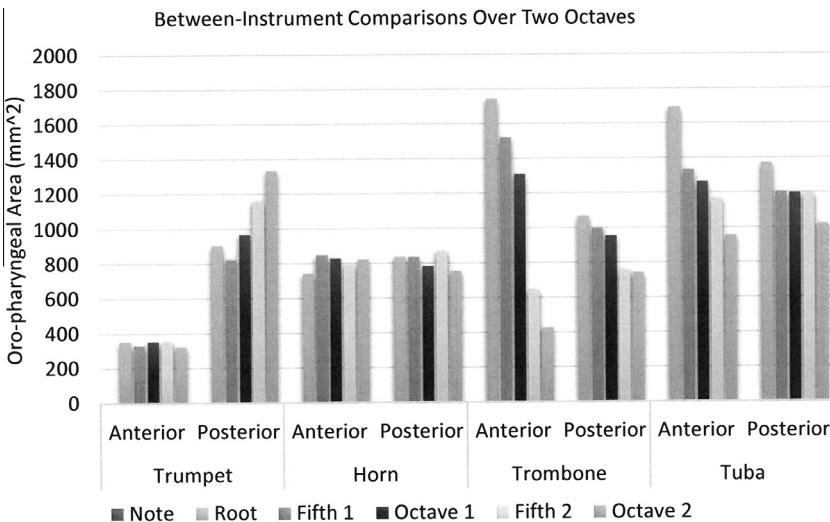


Fig. 7. Anterior and posterior oropharyngeal areas in trumpet, horn, trombone and tuba while executing the ascending five note exercise.

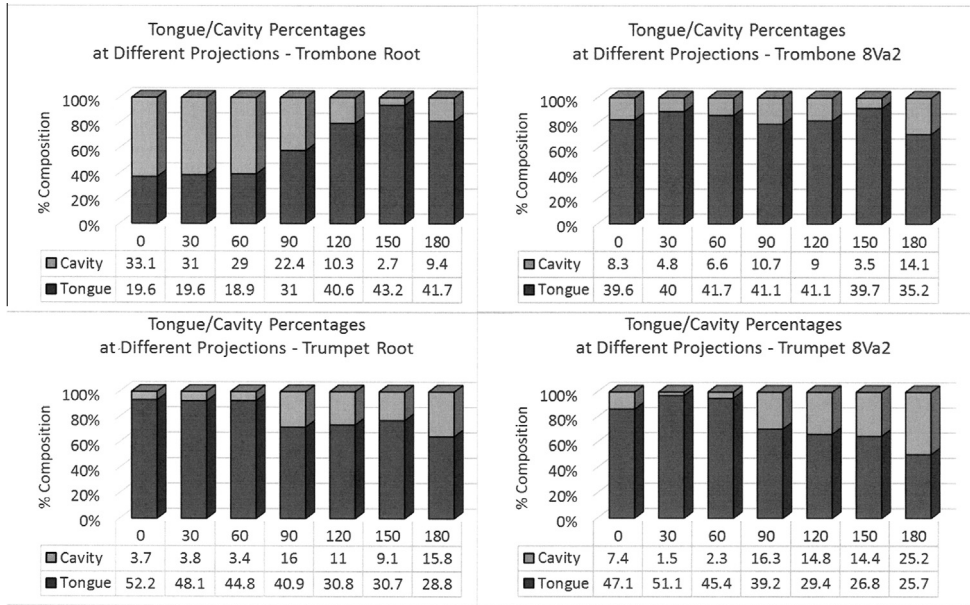


Fig. 8. Percent composition (tongue vs. cavity) of oropharyngeal area on lowest and highest notes (left and right respectively) for trombone (upper) and trumpet (lower) performers.




Fig. 9. Example of line profiles of the two movement components (profile line 1 = “T”, profile line 2 = “K”) of the tongue during the double tonguing exercise by the trombone player. Sagittal plane shows the lines positioned along the direction in which movement occurs.

TBN-double-tonguing). Fig. 9 depicts the sagittal view of a trombone artist (left panel), showing the two lines representing the main movement components of the tongue, associated with the “T” (Line 1, tongue tip) and the “K” (Line 2, back of the tongue). The two right panels show the respective line profiles versus time. In the top right panel, each spike represents the movement of the tongue anteriorly to contact the back of the front teeth to execute the “T” sound, and each valley represents retraction of the tip of the tongue as the back of the tongue rises to form the “K” sound. In the bottom

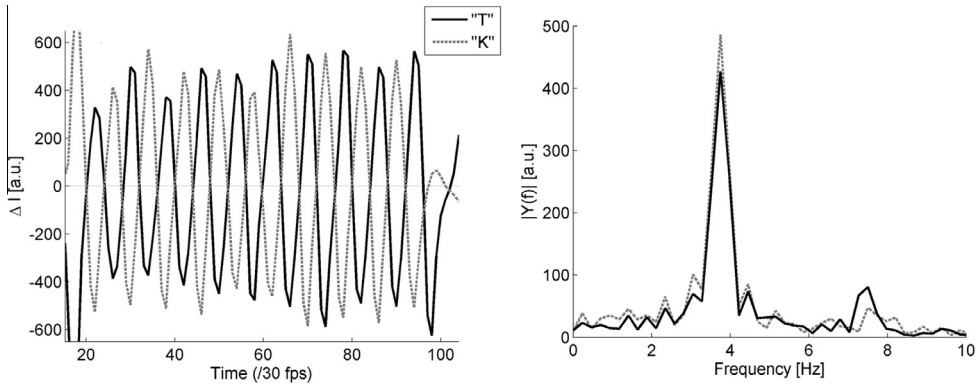


Fig. 10. Left panel shows double tonguing analysis of trombone player depicting anti-phase tongue tip “T” and back of tongue “K” displacement (arbitrary units). The right panel shows the Fourier analysis of the same double tonguing exercise.

right panel, upward and downward motions of the back of the tongue are depicted as similar spikes and valleys, but are out of phase with respect to movements of the tongue tip. The horizontal dashed lines indicate the estimated range of motion of the respective movement components.

Fig. 10 (left panel) shows the time series representing the activity of the tongue tip (“T”) and the back of the tongue (“K”) in the trombone player. The anti-phase relation between the two movement components is clearly revealed, characterized by high negative Pearson correlation of -0.92 in this example. The frequency of the respective movement components can be estimated from the peaks of the amplitude spectra, shown in right panel of Fig. 10. The number of notes per second is obtained by addition of the two peak frequencies.

Table 1 shows a summary of the range of motion, the correlation between the movement components, and the note rate for the four instrumentalists. The values were remarkably similar, suggesting that fast double-tonguing represents a specific type of movement, the execution of which is not instrument specific.

4. Discussion

The principal finding of the discrete analysis of the ascending five note exercise was that oropharyngeal adaptations differ between brass instruments as they move from lower to higher notes. For low brass instruments (trombone and tuba), these transitions featured a progressive decrease in the total oropharyngeal area, with decreases in the anterior portion accounting for most of the difference (see Fig. 7). This was accomplished by an alteration in the conformation of the tongue so that its anterior portion projected progressively upwards and forwards during ascending (Fig. 8, top two images). In contrast, the trumpet subject showed changes that were essentially in the opposite direction (slightly larger total area, notably larger posterior area, with a slight decrease in the anterior area). This was accompanied by a concomitant lowering of the posterior surface of the tongue (Fig. 8, bottom two images). The changes observed in the trumpet player showed some similarity to the results reported by Schumacher et al. (2013). We too found increases in the pharyngeal free space (posterior area in our study) during ascending notes for this instrumentalist. However, the Schumacher et al. data suggested a slight but insignificant increase in the oral free space while our subject demonstrated little if any change in our comparable measure, anterior area. The horn player demonstrated little change at all in any of our measures.

To explain these observations, recent work in the field of acoustical physics may prove useful. In a review by Wolfe, Garnier, and Smith (2009), the authors summarize evidence that brass and wind instrumentalists manipulate structures within the oropharyngeal spaces that modify the nature of the coupling between what they call the upstream duct (the oropharyngeal cavity) and the

Table 1

Comparisons between instruments of “T” and “K” ranges of motion, correlation coefficients between “T” and “K” movements, and note rates.

Instrument	ROM “T” [mm]	ROM “K” [mm]	<i>r</i>	Note rate [s ⁻¹]
Trumpet	15.0	15.8	−0.84	10.5
Horn	15.8	22.5	−0.95	8.2
Trombone	16.5	21.8	−0.92	7.5
Tuba	15.8	19.5	−0.89	11.7

downstream duct (the internal bore of the instrument). In brass players, these two ducts are separated by an oscillating valve (the vibrating lips), that can be directly affected by these manipulations. By combining changes in tension of the lips with morphologic alterations of the oropharyngeal cavity as well as with changes in the length of the instrument (via valves or a slide), the resulting tone can be greatly affected both in terms of pitch and harmonic characteristics (what instrumentalists call timbre). That players can and do actually tune the resonances of the vocal tract to reinforce different frequencies has been shown in trumpeters and trombonists (Chen, Smith, & Wolfe, 2011; Fréour & Scavone, 2013; Kaburagi, Yamada, Fukui, & Minamiya, 2011; Kaburagi et al., 2013) as well as in a didgeridoo performer (Fletcher et al., 2001).

In addition, from a fluid-mechanical perspective it can be hypothesized that the shaping of the oral cavity might play a role in supporting the required intra-oral pressure and air flow conditions during tone production in brass instruments. The combination of intra-oral pressure and air flow has shown to be dependent on instrument (Bouhuys, 1964), and within instruments, dependent on pitch and dynamic level (Bouhuys, 1964; Fréour, Caussé, & Cossette, 2010). Generally, larger instruments (e.g., the tuba) require a larger air flow, whereas smaller instruments (e.g., the trumpet) require a higher intra-oral pressure. Within instruments, pressure and air flow have been shown to increase with increasing dynamic level, whereas increasing pitch is accompanied by an increase of pressure and a decrease of air flow (Fréour et al., 2010). This might explain the observed tendencies that larger instruments and low registers are associated with larger oral cavities in order to support a large air flow, whereas high pressures in the high pitch range might be easier to obtain by narrowing the anterior part of the oral cavity. To date, the role of the oral cavity has hardly been explored in this respect. MRI measurements as presented here can contribute to a more complete understanding of such issues.

The analyses of the double-tonguing exercises show that the high-speed MRI technique employed in this study is capable of studying the kinematics of the tongue in fast articulatory movements. A methodology was presented, which allows for the extraction of time series data from the image sequences, representing dynamic information. In the specific case of double-tonguing we found no clear distinctions between the four instrumentalists with respect to the range of motion and the frequency of the tongue movement, suggesting that double-tonguing might be characterized as a specific movement pattern, independent of the type of instrument being played. Generally, this type of analysis has great potential to shed light on dynamic aspects of articulatory movements in instrument performance and speech production.

Teachers of brass instrumentalists have established guidelines for issues dealing with readily-seen physical phenomena associated with playing notes of increasing pitch, and these are well-documented in the pedagogy literature (Epstein, 2013; Farkas, 1962; Gardner, 2002; Reynolds, 1997; Rider, 2006) as well as in recent research (Schumacher et al., 2013). However, with respect to motor activity within the mouth and throat involving the tongue, soft palate and larynx, there is a clear need for further investigation to shed light on what occurs. Presumably, there may be patterns in successful players that exist which can now be elucidated and explained using MRI technology. However, more studies involving larger numbers of subjects will be required to determine how consistent these patterns are. For example, it has been shown that there is a degree of variability between trumpeters in accomplishing the same task, despite an over-all consistent trend (Schumacher et al., 2013). Unpublished data from our institution confirms this. Thus, it must be acknowledged that generalizing the results presented here to all brass players is tenuous, based upon the very few subjects examined.

5. Conclusions

This study affirms the utility of high-speed, real-time MRI in examining discrete and dynamic motor activity within the mouth and throat of brass players. Further, it provides insights into novel ways to describe, quantify and compare conformational changes occurring during tone production in different brass instruments as they play notes of different frequency. And finally, this work provides examples of a methodological approach that can fully appropriate the detailed information provided by high-speed (frame rate 30 Hz) MRI. To the author's knowledge, this is the fastest sampling rate used to date in examining oropharyngeal movement in musicians.

Future studies are clearly needed in order to determine whether consistent, normal patterns can be identified for brass instrumentalists. Much may be gained in the field of brass pedagogy should patterns that are consonant with successful performance be identified. Further, if normal patterns can be established, the use of this technology in comparative studies of movement disorders such as focal task-specific dystonia in brass musicians may be warranted. For example, there may be predictable conformational abnormalities in dystonia patients that become diagnostic and prognostic indicators. Further, it may be feasible that the purposeful manipulation of oropharyngeal structures in dystonia patients can provide a useful approach in sensory-motor retraining.

Finally, it is imperative that consistency be brought to studies attempting to establish these benchmark motor patterns. To that end, it seems logical to initially study elite performers of the various brass instruments. These individuals have presumably achieved movement strategies that are consistent with the highest level of success. While it is entirely possible that within such a sample, variations in approach may exist, it may also be that there are consistent baseline behaviors that are worthy of understanding and teaching. Additionally, consistency in terms of the performance devices used during MRI study is imperative. The current study utilized a resistance device, the B.E.R.P., for the performance tasks, and across different studies, different approaches have been utilized. While the limitations in terms of body position and performance device are considerable with MRI, we have recently acquired an MRI-compatible horn surrogate (Seraphinoff Historical Instruments, Bloomington, Indiana) that mimics the lengths, diameters and tapers of a natural horn in Eb, including a normal (non-ferromagnetic) bell. We have successfully tested this device and find it to be quite comparable in "feel" and timbre of a real instrument. In future studies, the use of this and other MRI-compatible instruments will better simulate real performance conditions, and should these studies include dystonia patients, the sensory feedback afforded will provide crucial similarity to that provided by actual orchestral instruments.

Appendix A. Supplementary data

Supplementary data associated with this article can be found, in the online version, at <http://dx.doi.org/10.1016/j.humov.2015.04.013>.

References

- Angerstein, W., Isselstein, A., Lindner, C., Aurich, V., & Massing, T. (2009). Ultraschalluntersuchungen der Zunge beim Spielen von Blasinstrumenten. *Musikphysiologie und Musikmedizin*, 16, 7–8.
- Bader, M. (2014). MB-Ruler. 2014. From <<http://www.markus-bader.de/MB-Ruler/index.php>>.
- Barkhausen, J., Goyen, M., von Winterfeld, F., Lauenstein, T., Arweiler-Harbeck, D., & Debatin, J. F. (2002). Visualization of swallowing using real-time TrueFISP MR fluoroscopy. *European Radiology*, 12, 129–133.
- Bouhuys, A. (1964). Lung volumes and breathing patterns in wind-instrument players. *Journal of Applied Physiology*, 19, 967–975.
- Chen, J. M., Smith, J., & Wolfe, J. (2011). Do trumpet players tune resonances of the vocal tract? *Journal of the Acoustical Society of America*, 131, 722–727.
- Echternach, M., Sundberg, J., Arndt, S., Breyer, T., Markl, M., Schumacher, M., et al (2008). Vocal tract and register changes analysed by real-time MRI in male professional singers—a pilot study. *Logopedics Phoniatrics Vocology*, 33, 67–73.
- Engwall, O. (2003). A revisit to the application of MRI to the analysis of speech production – testing our assumptions. In *Proceedings of the 6th international seminar on speech production*, Sydney.
- Epstein, E. (2013). *Horn playing from the inside out: A method for all brass musicians*. Eli Epstein Productions.
- Farkas, P. (1962). *The art of brass playing: A treatise on the formation and use of the brass player's embouchure*. Bloomington, Ind.: Brass Publications.

- Fletcher, N., Hollenberg, L., Smith, J., & Wolfe, J. (2001). The didjeridu and the vocal tract. In D. Bonsi, D. Gonzalez, & D. Stanzial (Eds.), *Proceedings of the international symposium on musical acoustics* (pp. 87–90). Perugia.
- Fox, F. (1974). *Essentials of brass playing: An explicit, logical approach to important basic factors that contribute to superior brass instrument performance*. Los Angeles: Fox.
- Fréour, V., Caussé, R., & Cossette, R. (2010). Simultaneous measurements of pressure, flow and sound during trumpet playing. In *Paper presented at the 10eme Congres Francais d'Acoustique, Lyon*.
- Fréour, V., & Scavone, G. P. (2013). Acoustical interaction between vibrating lips, downstream air column, and upstream airways in trombone performance. *Journal of the Acoustical Society of America*, 134, 3887–3898.
- Frucht, S. J. (2009). Embouchure dystonia—Portrait of a task-specific cranial dystonia. *Movement Disorders*, 24, 1752–1762.
- Frucht, S. J., & Estrin, G. (2010). “Losing one’s chops”: clues to the mystery of embouchure dystonia. *Neurology*, 74, 1758–1759.
- Gardner, R. (2002). *Mastering the Horn’s Low Register*. Richmond, Virginia: International Opus.
- Hagedorn, C., Proctor, M., Goldstein, L., Tempini, M., & Narayanan, S. (2012, 2012). Characterizing covert articulation in apraxic speech using real-time MRI. From <<http://sail.usc.edu/span/pdfs/hagedorncharacterizing.pdf>>.
- Horvath, K. A., Li, M., Mazilu, D., Guttman, M. A., & McVeigh, E. R. (2007). Real-time magnetic resonance imaging guidance for cardiovascular procedures. *Seminars in Thoracic and Cardiovascular Surgery*, 19, 330–335.
- Joseph, A., Kowallick, J. T., Merboldt, K. D., Voit, D., Schaetz, S., Zhang, S., et al (2013). Real-time flow MRI of the aorta at a resolution of 40 msec. *Journal of Magnetic Resonance Imaging*.
- Joseph, A. A., Merboldt, K. D., Voit, D., Zhang, S., Uecker, M., Lotz, J., et al (2012). Real-time phase-contrast MRI of cardiovascular blood flow using undersampled radial fast low-angle shot and nonlinear inverse reconstruction. *NMR in Biomedicine*, 25, 917–924.
- Kaburagi, T., Yamada, N., Fukui, T., & Minamiya, E. (2011). A methodological and preliminary study on the acoustic effect of a trumpet player’s vocal tract. *Journal of the Acoustical Society of America*, 130, 536–545.
- Kaburagi, T., Yamada, N., Fukui, T., & Minamiya, E. (2013). A morphological and acoustic study on the effect of a trumpet player’s vocal tract. *Journal of the Acoustical Society of America*, 133.
- Miller, C. A., Pearce, K., Jordan, P., Argyle, R., Clark, D., Stout, M., et al (2012). Comparison of real-time three-dimensional echocardiography with cardiovascular magnetic resonance for left ventricular volumetric assessment in unselected patients. *European Heart Journal Cardiovascular Imaging*, 13, 187–195.
- Ngo, C. W., Pong, T. C., & Zhang, H. J. (2003). Motion analysis and segmentation through spatio-temporal slices processing. *IEEE Transactions on Image Processing*, 12, 341–355.
- Niebergall, A., Zhang, S., Kunay, E., Keydana, G., Job, M., Uecker, M., et al (2013). Real-time MRI of speaking at a resolution of 33 ms: Undersampled radial FLASH with nonlinear inverse reconstruction. *Magnetic Resonance in Medicine*, 69, 477–485.
- Olthoff, A., Zhang, S., Schweizer, R., & Frahm, J. (2014). On the physiology of normal swallowing as revealed by magnetic resonance imaging in real time. *Gastroenterology Research and Practice*, 2014, 493174.
- Pan, X., Li, J., Ba, S., Zhang, Y., & Tang, S. (2006). Visual features extraction through spatiotemporal slice analysis. In T.-J. Cham, J. Cai, C. Dorai, D. Rajan, T.-S. Chua, & L.-T. Chia (Eds.), *Advances in multimedia modeling* (4352, pp. 304–313). Berlin Heidelberg: Springer.
- Rasband, W. S. (1997–2012). ImageJ, U.S. National Institutes of Health. From <<http://imagej.nih.gov/ij/>>.
- Reynolds, V. (1997). *The Horn Handbook*. In R. G. Pauly (Ed.). Portland, Oregon: Amadeus Press.
- Rider, W. (2006). *Real world horn playing*. San Jose, Calif.: W. Rider Publications.
- Schumacher, M., Schmoor, C., Plog, A., Schwarzwald, R., Taschner, C., Echternach, M., et al (2013). Motor functions in trumpet playing – A real-time MRI analysis. *Neuroradiology*, 55, 1171–1181.
- Steinmetz, A., Stang, A., Kornhuber, M., Rollinghoff, M., Delank, K. S., & Altenmüller, E. (2013). From embouchure problems to embouchure dystonia? A survey of self-reported embouchure disorders in 585 professional orchestra brass players. *International Archives of Occupational and Environmental Health*.
- Uecker, M., Zhang, S., Voit, D., Karaus, A., Merboldt, K. D., & Frahm, J. (2010). Real-time MRI at a resolution of 20 ms. *NMR in Biomedicine*, 23, 986–994.
- Uecker, M., Zhang, S., Voit, D., Merboldt, K. D., & Frahm, J. (2012). Real-time MRI: Recent advances using radial FLASH. *Imaging in Medicine*, 4, 461–476.
- Voit, D., Zhang, S., Unterberg-Buchwald, C., Sohns, J. M., Lotz, J., & Frahm, J. (2013). Real-time cardiovascular magnetic resonance at 1.5T using balanced SSFP and 40 ms resolution. *Journal of Cardiovascular Magnetic Resonance*, 15, 79.
- Wiggins, G. C., & Storey, P. (2010). Rapid frame-rate MR acquisitions to reveal mechanisms of circular breathing and sound production in the Australian Aboriginal didgeridoo. In *Proceedings of the international society of magnetic resonance in medicine* (Vol. 18).
- Wolfe, J., Garnier, M., & Smith, J. (2009). Vocal tract resonances in speech, singing, and playing musical instruments. *Human Frontier Science Program Journal*, 3, 6–23.
- Zhang, S., Block, K. T., & Frahm, J. (2010). Magnetic resonance imaging in real time: advances using radial FLASH. *Journal of Magnetic Resonance Imaging*, 31, 101–109.
- Zhang, S., Olthoff, A., & Frahm, J. (2012). Real-time magnetic resonance imaging of normal swallowing. *Journal of Magnetic Resonance Imaging*, 35, 1372–1379.
- Zhang, S., Uecker, M., Voit, D., Merboldt, K. D., & Frahm, J. (2010). Real-time cardiovascular magnetic resonance at high temporal resolution: Radial FLASH with nonlinear inverse reconstruction. *Journal of Cardiovascular Magnetic Resonance*, 12, 39.
- Zielke, A., Muth, T., Massing, T., & Angerstein, W. (2012). Zungenbewegungen und Gesichts-Hals-Motorik beim Spielen von Blasinstrumenten. *Musikphysiologie und Musikmedizin*, 3, 189–195.